

# Management of a patient with hypodontia, using implants and all-ceramic restorations: A clinical report

Bill Abbo, DDS,<sup>a</sup> and Michael E. Razzoog, DDS, MS, MPH<sup>b</sup>

Biologic and Materials Sciences, Division of Prosthodontics, University of Michigan, Ann Arbor, Mich

**A 16-year-old woman with congenitally missing permanent mandibular second premolars and central incisors presented for treatment. The prosthodontic treatment consisted of placing 2 internal tri-lobed narrow platform implants in the mandibular second premolar spaces, along with zirconium abutments and all-ceramic crowns. A 4-unit zirconium fixed partial denture was fabricated to restore the missing mandibular central incisors. (J Prosthet Dent 2006;95:186-9.)**

**H**ypodontia is a condition for which patients require extensive and complex treatments, ranging from single restorations to surgery and multiple restorations, coupled with lifelong maintenance.<sup>1</sup> It has been reported that along with tooth agenesis, there may be either deviant nerve canal courses and conditions, such as reduced width and height of bone, inclination of adjacent teeth, and supra-eruption of antagonist teeth.<sup>2,3</sup> While some authors believe that the etiology of hypodontia is largely unknown, others advocate either genetic factors such as hemoglobin SC<sup>4</sup> or environmental factors such as exposure to dioxins<sup>5</sup> during tooth development as the basis of the condition.<sup>6,7</sup> Excluding the third molars, the mandibular second premolars are the most frequently missing teeth, comprising between 60% to 72% of the total number of missing teeth.<sup>8</sup>

The dental literature contains reports<sup>9-11</sup> of various treatment solutions, from space maintenance to dental implants, all suggesting maintenance of the deciduous teeth until they are lost by exfoliation or root resorption, extracted due to caries, become ankylosed, or become a problem due to infraocclusion.<sup>12</sup> Once a plan of treatment has been finalized, the retained primary teeth may be removed and prostheses used to restore function and esthetics. Space closure via orthodontic movement is also another alternative discussed in the literature.<sup>13</sup> Depending on the location of the congenitally missing dentition, planned extractions may allow drift of the posterior molars to close the edentulous space.<sup>14</sup> Since the pioneering work of Branemark,<sup>15</sup> the use of osseointegrated implants to aid in restoring missing teeth has become the treatment of choice for patients with all forms of hypodontia.<sup>16</sup>

Another relatively new treatment modality is the all-ceramic fixed partial denture (FPD). With the increasing emphasis on patient esthetics, new all-ceramic systems for FPD restorations have been introduced; however, most of these systems are still being evaluated for their long-term success in clinical studies.<sup>17,18</sup> McLean<sup>19</sup> first

introduced all-ceramic FPDs in 1967. Recently, the development of a 1-piece zirconium FPD appears to address many of the concerns regarding the strength of these restorations.<sup>17,20</sup> This clinical report describes the rationale and treatment of a patient with hypodontia using implants and all-ceramic restorations.

## CLINICAL REPORT

A 16-year-old white woman reported to the University of Michigan Department of Prosthodontics with a chief complaint that her front teeth were “small and ugly,” and she was “missing some back teeth.” The intraoral and radiographic examination corroborated that the patient was missing maxillary and mandibular permanent second premolars, as well as the 2 mandibular central incisors (Figs. 1, 2, and 3). At the time of the examination, an orthodontic retainer was used to maintain the edentulous space of the mandibular second premolars. Although the permanent mandibular central incisors had not developed, the 2 deciduous central incisors were present, as well as the deciduous maxillary second molars, which were maintaining the space for eventual replacement. A review of the medical and dental history revealed no significant medical findings, and the parents denied knowledge of any condition linked to the hypodontia. There were no medical findings to contraindicate dental care, including elective surgery. The patient had completed a full course of orthodontic treatment 2 months prior to her consultation visit. An occlusal analysis determined that the patient presented with canine protected articulation, with all other teeth disengaging in the excursive movements of the mandible. A consultation with the treating orthodontist was made to assess completion of patient growth. The lateral cephalographs (pretreatment and posttreatment) that were made at a 2-year interval were evaluated, and it was determined that growth was completed, enabling an FPD and dental implants as treatment options.

Several treatment options were presented to the patient and parents to develop a functional and esthetic dentition. The parents declined surgical procedures

<sup>a</sup>Graduate student.

<sup>b</sup>Professor.

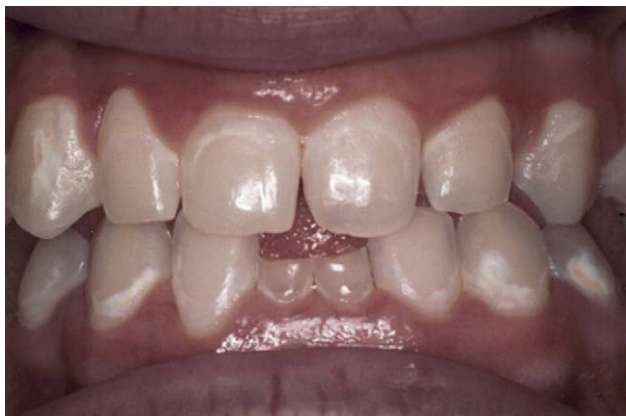

Fig. 1. Pretreatment frontal view.

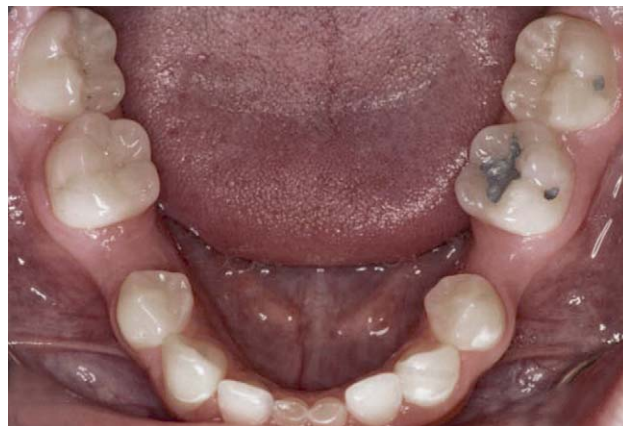

Fig. 2. Pretreatment mandibular occlusal view.

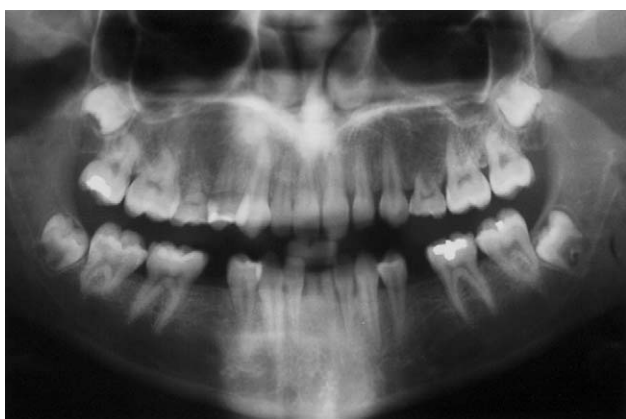

Fig. 3. Pretreatment panoramic radiograph.

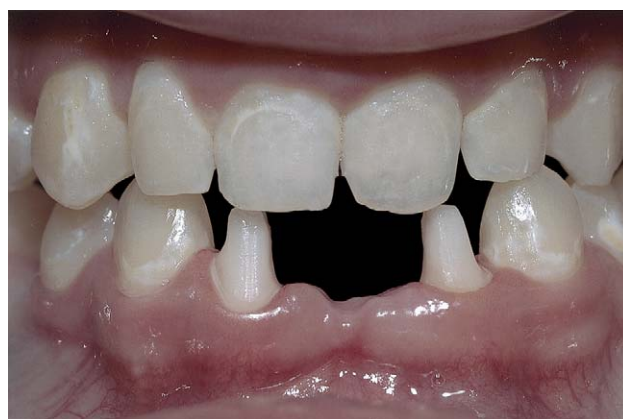

Fig. 4. Tooth preparation for 4-unit zirconia FPD.

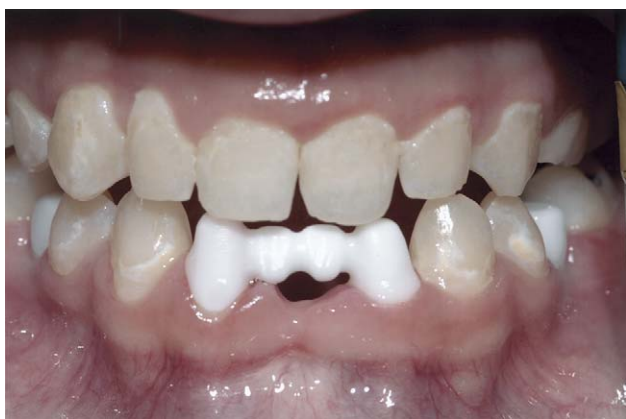

Fig. 5. Trial insertion of FPD.

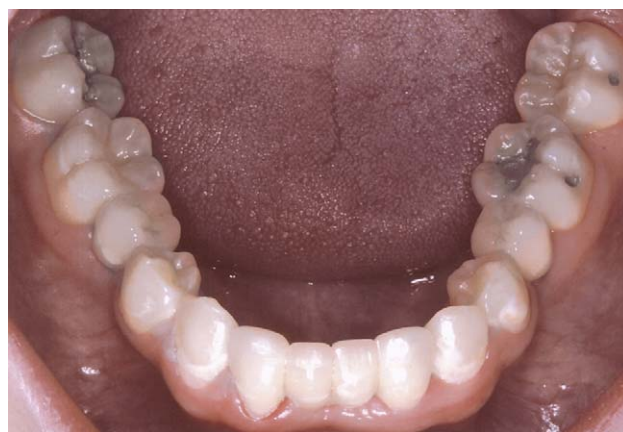
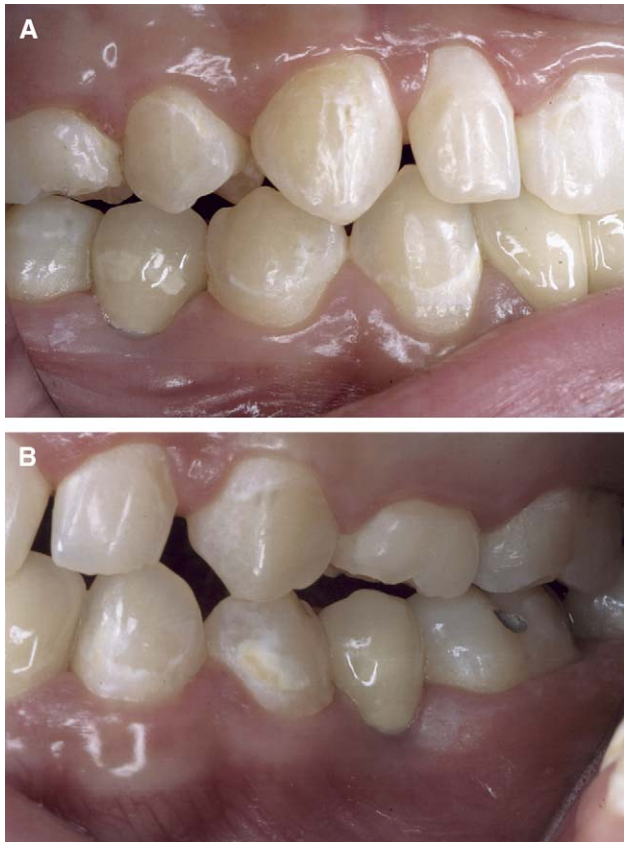
Fig. 6. Occlusal view of definitive prosthesis.

involving grafting of potential implant sites, treatment with a resin-bonded FPD, or use of removable prostheses to replace the missing teeth. Due to the limited bone width associated with the mandibular anterior edentulous region, an implant-supported restoration was not an option, even using a narrow-diameter implant.

With these findings, an FPD was the only restorative solution for the missing mandibular anterior teeth. It was determined that the premolars could be replaced with narrow-platform (NP) 3.5-mm implants (Nobel Biocare AB, Goteborg, Sweden), ceramic abutments, and all-ceramic esthetic restorations (both from

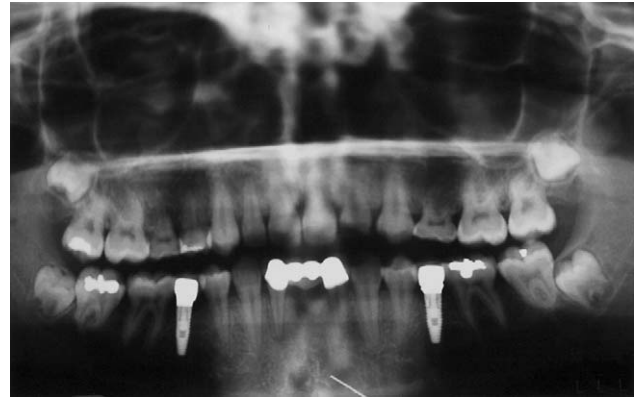


**Fig. 7.** **A**, Definitive prosthesis viewed from the right. **B**, Definitive prosthesis viewed from the left.

Procera; Nobel Biocare AB). The treatment in the maxillary arch was to be phased with the rest of the treatment due to financial constraints. Because the primary first molars had an acceptable root structure and were caries-free, treatment phasing was determined appropriate. The primary first molars would be retained and monitored until further treatment was deemed necessary.

The NP implants were chosen due to the lack of sufficient bone width to provide 2 mm of bone on the buccal and lingual of the implant<sup>21</sup> necessary for a regular-platform 4.3-mm implant, and in consideration of the parents' wish for no additional grafting to improve the width. All excursive movements could be achieved on the natural dentition. The restoration of the anterior mandibular edentulous space with an all-ceramic FPD and placement of implant-retained all-ceramic crowns was determined to be conservative, while still providing acceptable functional and esthetic results. The NP dental implants were placed using a surgical guide in the mandibular second premolar spaces, and were allowed to integrate for 4 months prior to the reconstruction.

An implant-level closed-tray impression was made using vinyl polysiloxane impression material (Kerr, Romulus, Mich) to record the location of the implants.



**Fig. 8.** Posttreatment panoramic radiograph.

Two custom zirconium abutments were fabricated using a 3-dimensional computer-assisted design (3-D CAD) program (Procera; Nobel Biocare AB). The abutments were then digitized, and copings were fabricated in zirconium (Procera; Nobel Biocare AB).

Due to the diminutive size of the mandibular lateral incisors, tooth preparations were completed with the minimal occlusal and axial reduction (1.5 mm and 0.9 mm, respectively) and a moderate chamfer margin (Fig. 4). An impression of the abutment copings and tooth preparations was made with vinyl polysiloxane (Kerr). The impression was poured in type V gypsum material (Die-Keen; Heraeus Kulzer, Armonk, NY). The dies were digitized using a touch-probe scanner (Forte Procera; Nobel Biocare AB), and the files were sent to the production facility in Stockholm, Sweden for fabrication of the 4-unit FPD (Fig. 5). The veneering porcelain (NobelRondo; Nobel Biocare AB) was applied to complete the esthetic portion of the crowns and the FPD. At insertion, the healing abutments were removed and ceramic custom abutments were placed and secured using 35-N·cm torque. The access opening was filled with cotton, and the all-ceramic crowns were placed onto the abutments to verify marginal integrity, occlusal relationships, and esthetic results. The all-ceramic restorations were cemented onto the implant abutments using a provisional cement marketed for use with dental implant restorations (Premier; Premier Dental Products Co, Plymouth, Pa).

The 4-unit FPD was placed onto the tooth abutments and evaluated for marginal integrity, occlusal relationships, and esthetic outcome. The margins of the FPD were all supragingival, which facilitated the visual and tactile assessment of the marginal integrity. When the patient and parents were satisfied with the esthetic result, the teeth were pumiced (Whip Mix Corp, Louisville, Ky) and treated with chlorhexidine (Zila Pharmaceuticals, Phoenix, Ariz), and the internal surface of the FPD was cleaned with alcohol. A thin coat of resin-modified glass-ionomer cement (FujiCem; GC Corp, Tokyo,



Japan) was placed into the internal surface of the all-ceramic FPD and placed with finger pressure (Figs. 6 and 7). For the first year after treatment, the patient was followed for routine hygiene and assessment of long-term outcome (Fig. 8). The patient acknowledged having improved function and esthetics, and was pleased with the results.

## SUMMARY

The use of all-ceramic implant abutments and restorations is a treatment modality for replacing missing teeth, and provides patients with functional and esthetic restorations. With the advancement of 3-D CAD technology, consistent and predictable all-ceramic restorations can be achieved.

The authors thank Lisa Kaake, Ceramist, Davidson Dental Laboratories, Inc, Flint, Mich.

## REFERENCES

- Hobkirk JA, Brook AH. The management of patients with severe hypodontia. *J Oral Rehabil* 1980;7:289-98.
- Lindqvist B. Extraction of the deciduous second molar in hypodontia. *Eur J Orthod* 1980;2:173-81.
- Kpkich VO Jr, Kinzer GA. Managing congenitally missing lateral incisors. Part I: canine substitution. *J Esthet Restor Dent* 2005;17:5-10.
- Oredugba FA. Hypodontia in an adolescent with the HbSC genotype: a case report. *Int J Paediatr Dent* 2005;15:455-8.
- Maurin JC, Bleicher F, Magloire H. Clinical consequences of dioxins exposure during tooth development. *Arch Pediatr* 2005;12:1636-40.
- Basdra EK, Kiokpasoglou MN, Komposch G. Congenital tooth anomalies and malocclusions: a genetic link? *Eur J Orthod* 2001;23:145-51.
- Brook AH. A unifying aetiological explanation for anomalies of human tooth number and size. *Arch Oral Biol* 1984;29:373-8.
- Svedmyr B. Genealogy and consequences of congenitally missing second premolars. *J Int Assoc Dent Child* 1983;14:77-82.
- Murdock S, Lee JY, Guckes A, Wright JT. A costs analysis of dental treatment for ectodermal dysplasia. *J Am Dent Assoc* 2005;136:1273-6.
- Kinzer GA, Kokich VO Jr. Managing congenitally missing lateral incisors. Part II: tooth-supported restorations. *J Esthet Restor Dent* 2005;17:76-84.
- Savarrio L, McIntyre GT. To open or to close space—that is the missing lateral incisor question. *Dent Update* 2005;32:16-25.
- Forgie AH, Thind BS, Larmour CJ, Mossey PA, Stirrups DR. Management of hypodontia: restorative considerations. Part III. *Quintessence Int* 2005;36:437-45.
- Fekonja A. Hypodontia in orthodontically treated children. *Eur J Orthod* 2005;27:457-60.
- Thilander B, Odman J, Grondahl K, Friberg B. Osseointegrated implants in adolescents. An alternative in replacing missing teeth? *Eur J Orthod* 1994;16:84-95.
- Branemark PI. Introduction to osseointegration. In: Branemark PI, Zarb GA, Albrektsson T, editors. *Tissue-integrated prostheses*. Chicago: Quintessence; 1985. p. 11-7.
- Dhanrajani PJ. Hypodontia: etiology, clinical features, and management. *Quintessence Int* 2002;33:294-302.
- Luthy H, Filser F, Loeffel O, Schumacher M, Gauckler LJ, Hammerle CH. Strength and reliability of four-unit all-ceramic posterior bridges. *Dent Mater* 2005;21:930-7.
- Sundh A, Molin M, Sjogren G. Fracture resistance of yttrium oxide partially-stabilized zirconia all-ceramic bridges after veneering and mechanical fatigue testing. *Dent Mater* 2005;21:476-82.
- McLean JW. High-alumina ceramics for bridge pontic construction. *Br Dent J* 1967;23:571-7.
- Suarez MJ, Lozano JF, Paz Salido M, Martinez F. Three-year clinical evaluation of In-Ceram Zirconia posterior FPDs. *Int J Prosthodont* 2004;17:35-8.
- Misch CE. *Contemporary implant dentistry*. 2nd ed. St. Louis: Elsevier; 1998. p. 89-118.

### Reprint requests to:

DR BILL ABBO  
715 SOUTH FOREST AVE APT. 203  
ANN ARBOR, MI 48104  
FAX: 734-764-1481  
E-MAIL: abbovan@umich.edu

0022-3913/\$32.00

Copyright © 2006 by The Editorial Council of *The Journal of Prosthetic Dentistry*.

doi:10.1016/j.prosdent.2006.01.007

### Receive Tables of Contents by E-mail

To receive tables of contents by e-mail, sign up through our Web site at <http://www.journals.elsevierhealth.com/periodicals/ympr>.

#### Instructions

Log on and click "Register" in the upper right-hand corner. After completing the registration process, click on "My Alerts," then "Add Table of Contents Alert." Select the category "Mosby" or type *The Journal of Prosthetic Dentistry* in the search field and click on the Journal title. The title will then appear in your "Table of Contents Alerts" list.

Alternatively, if you are logged in and have already completed the Registration process, you may add tables of contents alerts by accessing an issue of the Journal and clicking on the "Add TOC Alert" link.

You will receive an e-mail message confirming that you have been added to the mailing list.

Note that tables of contents e-mails will be sent when a new issue is posted to the Web site.